

Juraj Brozović

Specialist in Oral Surgery.
Assistant Professor, Faculty of Dental
Medicine and Health Osijek.
Doctor of Dental Medicine.



Collagenous socket preservation after atraumatic extraction

The patient, a healthy 57-year-old male with good oral hygiene, presented with multiple deficient old composite restorations and no pain. He was diagnosed with premolar root fracture (tooth 35). After atraumatic extraction, in order to avoid excessive resorption of the alveolar bone, socket preservation was performed using SeptoCone - a high-density collagen cone - providing blood clot stabilization and thus facilitating bone healing. A single implant was placed, showing a stable outcome at 6 years follow-up.

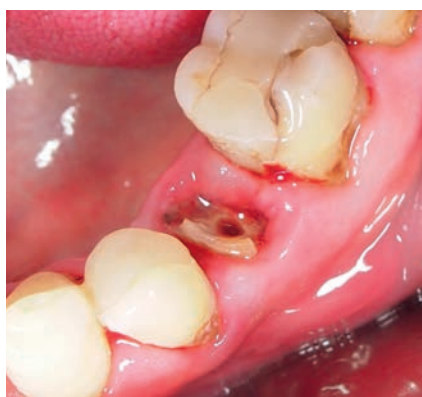

Fig. 01 - Clinical situation - tooth 35.

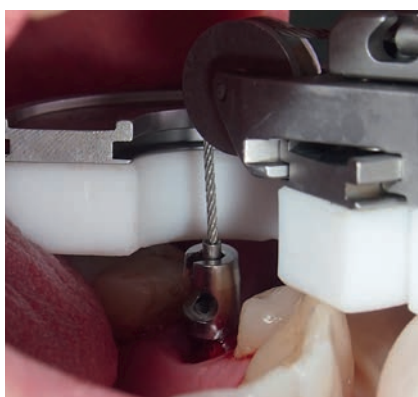


Fig. 02 - The tooth is atraumatically extracted with the Benex system, keeping maximum alveolar bone walls intact.

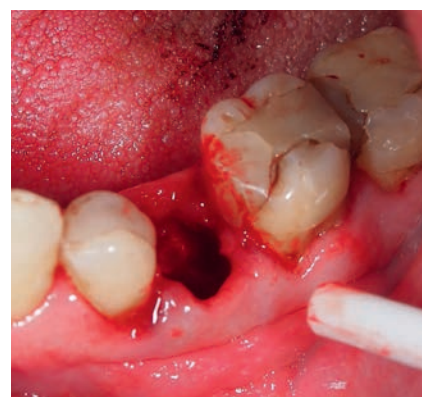

Fig. 03 - Thorough curettage of the socket is performed after atraumatic extraction.

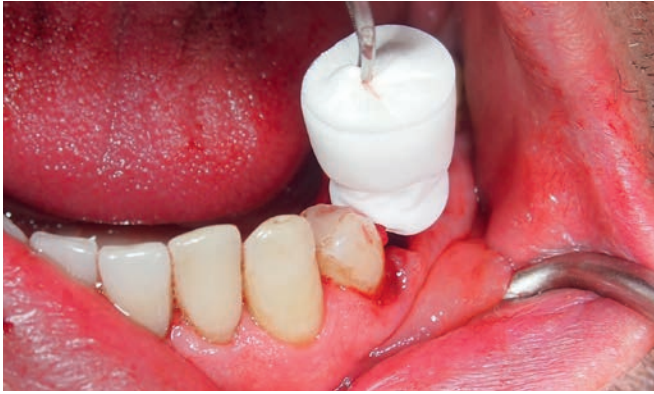

Fig. 04 - SeptoCone is placed in the empty socket of the single-rooted premolar site. The cone can be gently compressed with the fingers to fit the socket shape.

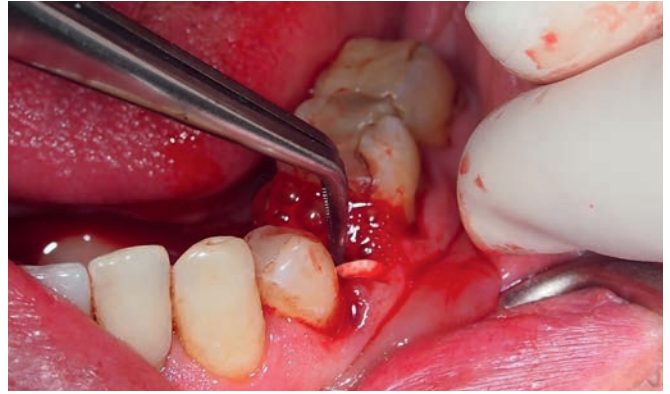

Fig. 05 - SeptoCone can be safely pushed to the extreme bottom of the root using gentle pressure.

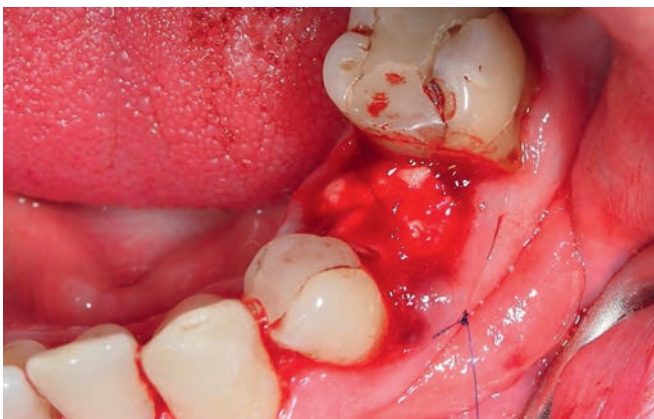


Fig. 06 - A cross-mattress (x) suture is placed to avoid the loss of cone while swallowing or chewing in the first hours. Recommended suture type is a fast-absorbing suture of 5-0 or less. SeptoCone allows open healing, per great collagen mass.

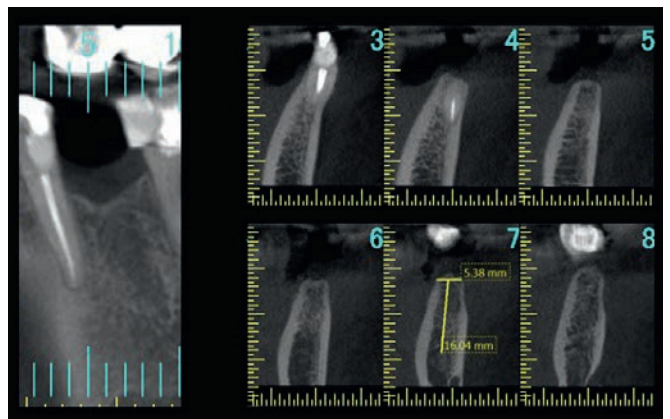


Fig. 07 - Follow-up CBCT at four months post-extraction. The extraction socket is completely remodeled with new woven bone.

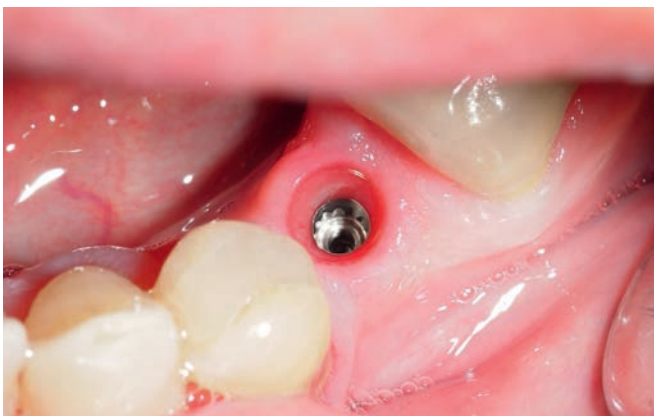

Fig. 08 - Six months after uneventful hard and soft tissue healing, an implant is placed in the site of tooth 35.

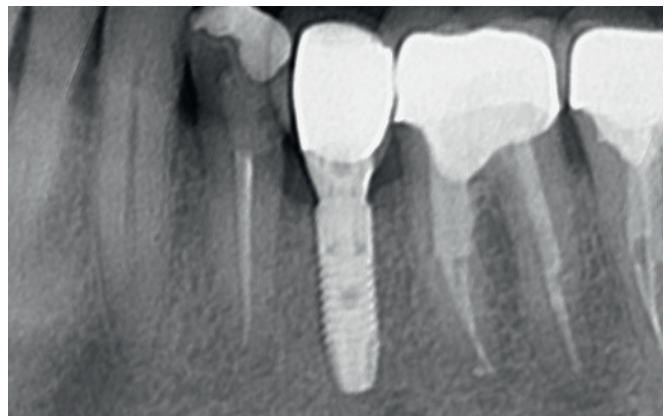


Fig. 09 - Follow-up x-ray at 6 years.