

References

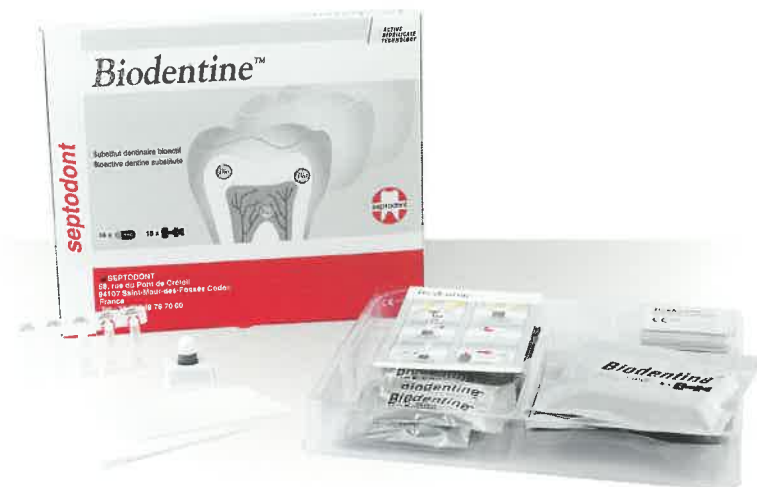

Authors	Title	Journal	Year	Ref.
Taha & Abdelkhader	Outcome of full pulpotomy using Biodentine in adult patients with symptoms indicative of irreversible pulpitis	IEJ	2018	1
Taha & Abdelkhader	Full Pulpotomy with Biodentine in Symptomatic Young Permanent Teeth with Carious Exposure	JOE	2018	2
Bakhtiar	Human Pulp Responses to Partial Pulpotomy Treatment with TheraCal as Compared with Biodentine™ and ProRoot MTA: A Clinical Trial	JOE	2017	3
Atmeh	Dentin-cement Interfacial Interaction: Calcium Silicates and Polyalkenoates	JDR	2012	4
Parker, Schneegurt et al.	Microbiology	Openstax	2016	5
Duncan et al.	European Society of Endodontology position statement: management of deep caries and the exposed pulp	IEJ	2017	6
Uesrichai et al.	Partial pulpotomy with two bioactive cements in permanent teeth of 6-to-18-year-old patients with signs and symptoms indicative of irreversible pulpitis: a non-inferiority randomised controlled trial	IEJ	2019	7

Presentation

Available in:

- Box of 15 capsules and 15 single-dose containers



Septodont - Units R & S - Orchard Business Centre - St Barnabas Close - Maidstone - ME16 0JZ - UK

Tel. : +44 (0)1622 695520 - Fax : +44 (0)1622 695521 - E-mail: information@septodont.co.uk

Please visit our website for more information:

www.septodont.co.uk



Updated Indications**

Reverse the Irreversible!*



Irreversible Pulpitis

ACTIVE
BIOSILICATE
TECHNOLOGY

Biodentine™

Dentine Substitute



*If haemostasis cannot be achieved after full pulpotomy, a pulpectomy and a RCT should be carried out, provided the tooth is restorable (ESE Position Paper, Duncan et al. 2017)
**Irreversible Pulpitis covered under new CE mark from 27 November 2019

Biodentine™ saves pulps **EVEN** with signs & symptoms of irreversible pulpitis



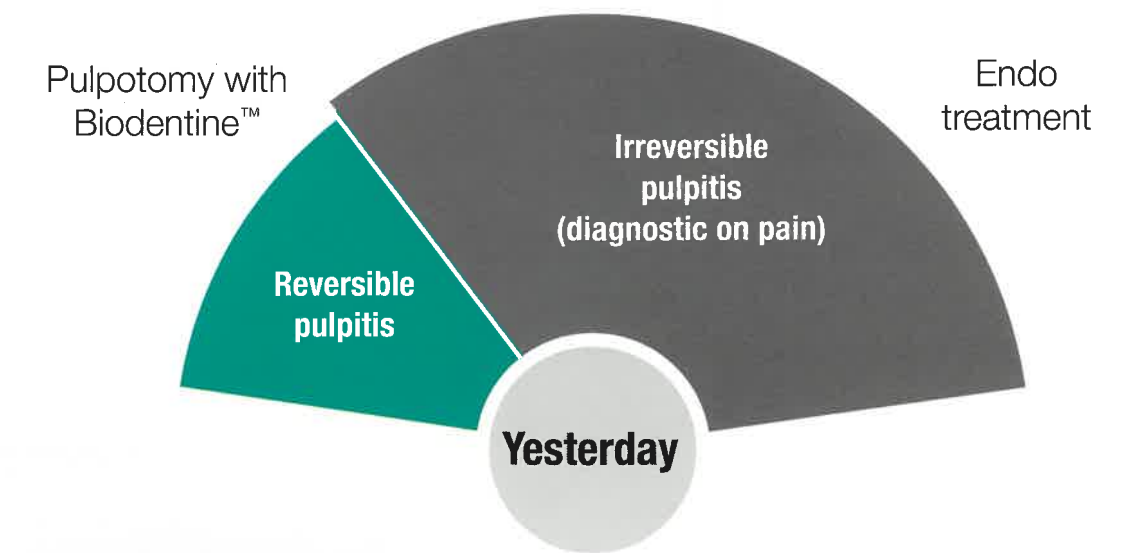
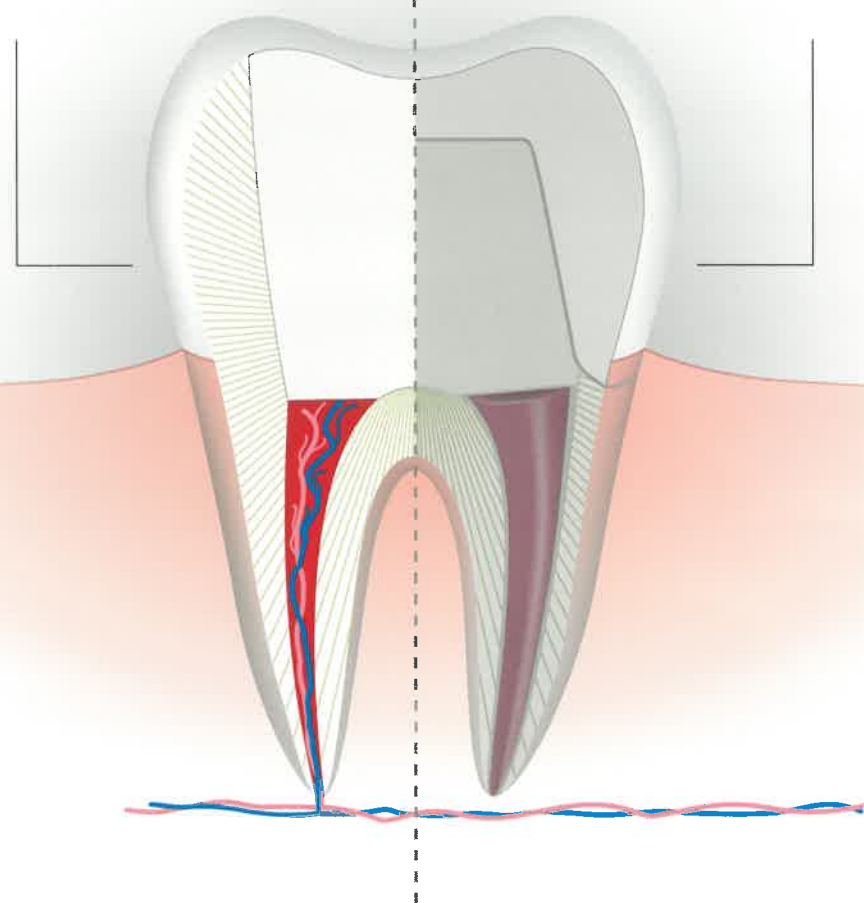
Vital Pulp Therapy

If you use **Biodentine™**

Minimally invasive vital pulp therapy

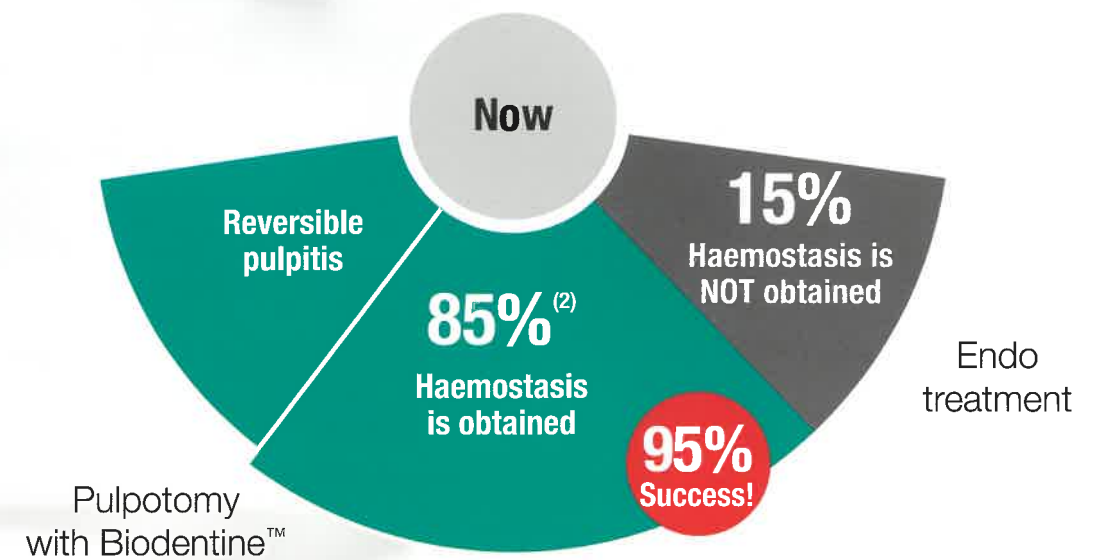
If not

Root Canal Treatment



Pulpotomy + Biodentine™

Could save up to 85% of teeth showing irreversible pulpitis⁽²⁾



Supported by ESE recommendations

“ After pulp exposure, during a pulp capping, partial pulpotomy, or full pulpotomy a hydraulic calcium silicate material should be placed directly onto the exposed pulp prior to definitive restoration⁽⁶⁾

Approved in CE Mark registration*

- Biodentine™ instructions updated with latest recommendations
- Approved treatment option for irreversible pulpitis

*If haemostasis cannot be achieved after full pulpotomy, a pulpectomy and a RCT should be carried out, provided the tooth is restorable (ESE Position Paper, Duncan et al. 2017)

Biodentine™ Clinical benefits



Minimally invasive treatment to preserve tooth structure

Immediate pain relief for your patient⁽¹⁾

Vital Pulp Therapy
- **normal root development** of immature permanent teeth⁽²⁾
- **complete** dentine bridge formation⁽³⁾

Strong sealing properties through tubules infiltration⁽⁴⁾

Mineralization of dentinal structure⁽⁴⁾

Alkaline pH (>11) limiting bacterial growth⁽⁵⁾

No tooth discoloration

Validated by clinical studies^(1, 2, 7)

3 clinical studies since 2017

114 treated teeth

95,6% average success rate

Clinical success rate of pulpotomies after irreversible pulpitis with Biodentine™

100%



Taha
2017

100%



Taha
2018

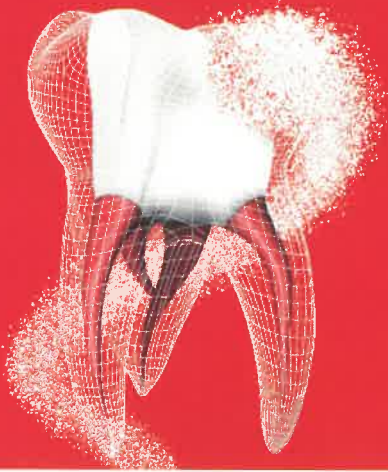87%



Uesrichai
2019

Managing carious pulp exposure

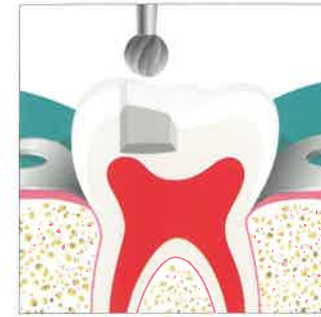E.S.E* Clinical Directions



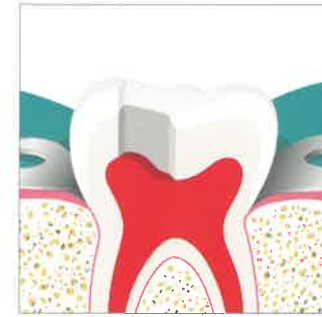- ▶ For class II capping of deep carious lesions an enhanced protocol should be used; including magnification, a disinfection irrigant and the application of a hydraulic calcium silicate cement.
- ▶ Carious exposure with symptoms indicative of irreversible pulpitis, when no rubber dam being used and instruments contaminated during caries removal, should be treated aseptically with pulpectomy.
- ▶ Alternatively full pulpotomy may be successful using an aseptic technique in cases where there is partial irreversible pulpitis in the coronal pulp.

* European Society of Endodontology

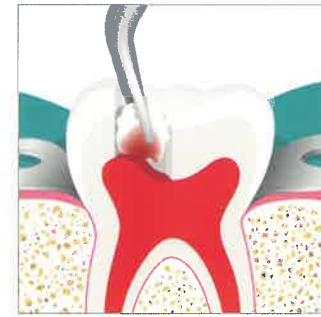Biodentine™: Step by step procedure



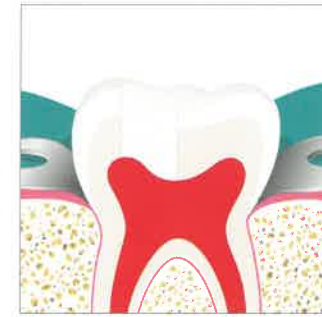Proceed to caries excavation, first rinsing with 5% NaOCl, then using regular carbide/diamond burs.



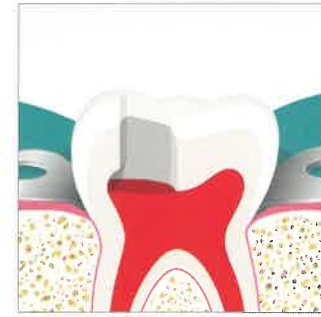Let the pulp appear and allow bleeding.



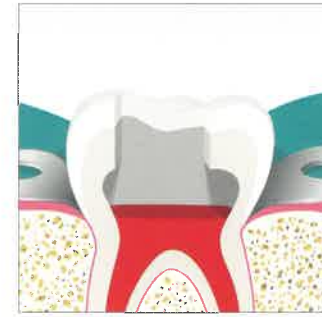Control bleeding by applying a cotton pellet, moistened with 5% NaOCl.



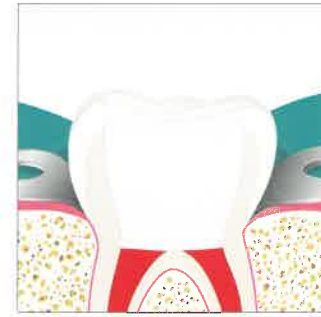If bleeding control is achieved within 5 min, fill the cavity with Biodentine™ and proceed to final enamel restoration within 6 months.



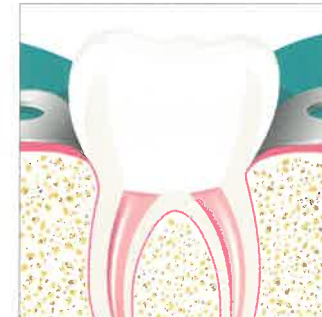If not, remove a part of the pulp (partial pulpotomy) and resume attempt to control bleeding within 5 min.



Perform progressive pulpotomy until bleeding control is achieved within 5 min.



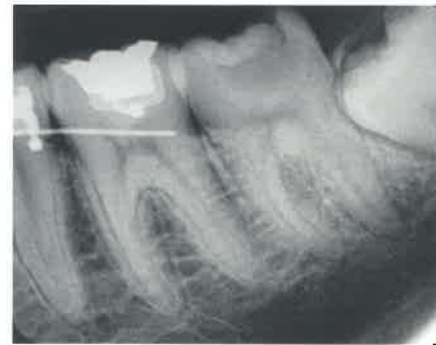When the root canal entries are visible (full pulpotomy) and bleeding is controlled within 5 min, fill the cavity with Biodentine™ and proceed to final enamel restoration within 6 months.



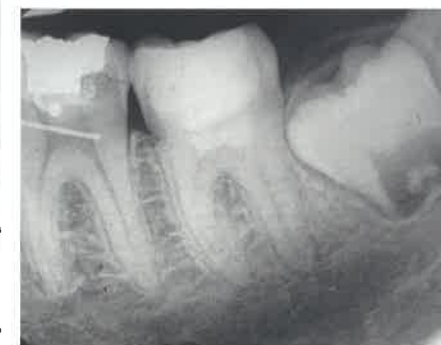If bleeding control within 5 min is impossible to achieve, then do the root canal treatment of the tooth.

Biodentine™: Clinical cases

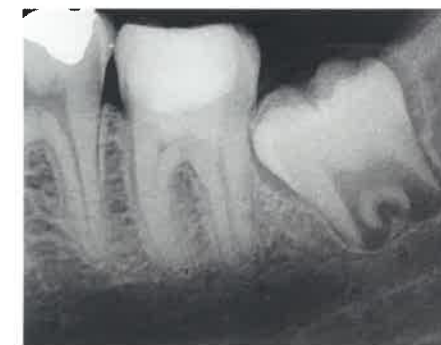Nineteen year old male patient complains of severe pain in lower left seven. Deep occlusal - Buccal caries exposing the pulp on the periapical radiograph. Tooth tender to percussion, responding to cold test with an exaggerated lingering pain compared to control. Full pulpotomy was performed, haemostasis was achieved in 4 minutes. Biodentine was placed as capping material and the tooth was restored with liner and resin composite. At 12 months, the tooth is asymptomatic with normal periapical architecture.



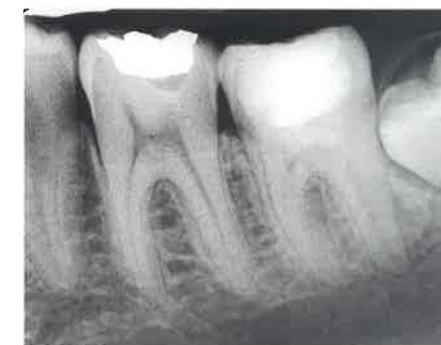Pre-op



Immediate post-op



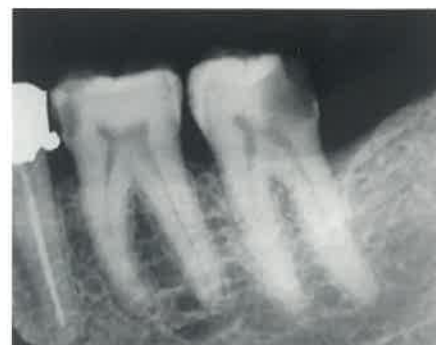6-month follow-up



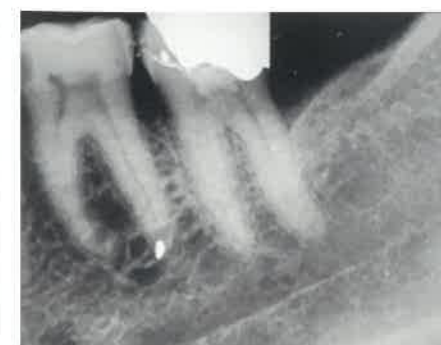12-month follow-up

Clinical Cases : Dr. Nassim Taha, Jordan

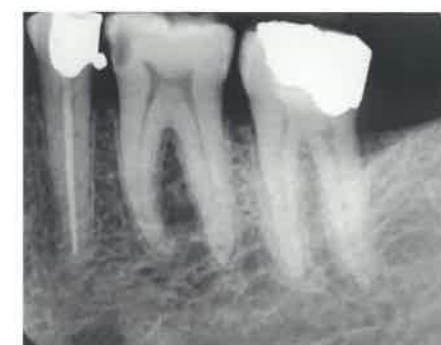Forty-five year old female complains of severe pain in the lower left seven. On examination the tooth is non tender to percussion, with deep distal caries exposing the pulp on the periapical radiograph. The tooth responded to cold test with lingering pain compared to control. Full pulpotomy was performed and haemostasis was achieved in 4 minutes. Biodentine was used as the capping material and the tooth was subsequently restored with liner and resin composite. At 12 months, the tooth is asymptomatic with normal periapical architecture.



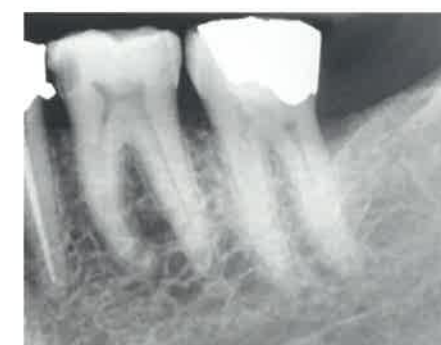Pre-op



Immediate post-op



6-month follow-up



12-month follow-up

Clinical Cases : Dr. Nassim Taha, Jordan